

FORM COMPAA.

(See Rules 253 (c)(iii), 254(80 255(i)(iv)

REPORT ABOUT THE MOTOR VEHICLES ACCIDENTS

| | | |
|----|--|--|
| 1 | Name of the Police Station | Arthapur |
| 2 | CR.No./TAR No. SDE No. | 273/2017 u/s 279, 304(A),IPC |
| 3 | Date, Time and Place of the accident | 11/10/2017 at 13.00 hrs. Nanded to Hinogoli Road Pardi Tq. Ardhapur |
| 4 | Name of the Injured/Deceased | Sahebrao Kishan Kanode age 35 year R/o. Ardhapur |
| 5 | Name of Hospital to which he/she was removed | Government Hospital Nanded. |
| 6 | Number of vehicles and type of the vehicle | MH-26-AB-8760 Truck |
| 7 | Name and address of the Driver of the vehicle with particulars or driving license of the said Driver and the address of the Issuing Authority of the said Driving License. The number of Badge in case of Public Service Vehicle and the address of the Issuing Authority of the said Badge. | Ramrap Gangaram Gawale 34 year R/o. Sambhaji chowk Nanded AP-25-605600705 R.T.O. Nizamabad |
| 8 | Name and Address of the Owner of the vehicle as it stands on the date of the accident | Santosh Suryakantrao Amilkanthaly R/o. Mugat Tq. Mudkhed |
| 9 | Name and address of the insurance Company with whom the vehicle was insured and the Divisional office of the said insurance Company | United Insurance Company Limited |
| 10 | Number of Insurance Policy/Insurance Certificate and the date of Validity of the insurance Policy/Insurance Certificate. | 2306003116 P 109708265 21/10/2017 |
| 11 | Action taken if any and the result there of | An offence has been registered against the accused. After completion of investigation Charge-sheet has been submitted. |

Inspector of Police
Police Station Ardhapur

फिर्याद

दि. १२/१०/२०१७

मी सुरेश विश्वांबर साखरे वय ३३ वर्ष व्यवसाय-शेती रा.गणपुर ता.अर्धापुर जि.नांदेड हल्ली मुक्काम कृष्णानगर अर्धापुर ता.अर्धापुर जि.नांदेड, मो.नं. - ९९७००२२७००


समक्ष पो.स्टे.अर्धापुर येथे येवून जबाब देतो कि मी वरील प्रमाणे राहणारा असून शेती व एल. आय.सी.एजंट व्यवसाय करतो.काल दि.११/१०/२०१७ रोजी दूपारी ०१.०० वाजताचे दरम्यान मी व माझे मित्र माधव भिमराव चव्हाण वय ४० वर्ष व्यवसाय-टेलर रा.अर्धापुर असे दोघे जण माझ्या मोटारसायकलमध्ये पेट्रोल भरण्यासाठी मोटारसायकल घेवून अर्धापुर ते वारंगगा रोडवर स्वातंत्र सेनानी पेट्रोलपंपावर जात असतांना पेट्रोलपंपाचे जवळ आमचे समोरून वारंगगाकडून अर्धापुरच्या दिशेन एक ट्रक त्याचा क्रमांक MH-२६/AD-८७६० हा भरधाव वेगाने येत होती. एक मोटार सायकल क्रमांक MH-२६/P-३०१८ ही सुध्दा वारंगगाकडून अर्धापुरचे दिशेने येत असतांना ट्रकचा वेग मर्यादपेक्षा जास्त असल्याने ट्रक चालकाने मोटार सायकलला पाठीमागुन धडक दिली. मोटार सायकलवर दोन इसम मोटार सायकल सह जोरात डिव्हायडरला आदळून बाजुला पडले व त्यांना गंभीर दुखापत झाली. आम्ही दोघे जन ताबडतोब त्या दोघांचे जवळ गेलो व त्यांना उठवून बसविले. मी त्या जखमी असलेल्या दोघांनाही चांगल्या प्रकारे ओळखतो. जखमी पैकी एक जन साहेबराव किशनराव कानोडे हे आमचे गावातील व आमचे नात्यातीलच आहेत. तर दुसरा जखमी ईसम संभाजी लक्ष्मण कदम हा रोडगी ता.हादगाव येथील असून तो साहेबराव चा मित्र असल्यामुळे नेहमी आमचे गावात जात व येत असतो आणि तो सध्या अर्धापुर येथेच किरायाने राहत होता.

आम्ही ट्रक चालकास नांव, गाव विचारले असता त्याने त्याचे नांव रामराव गंगाराम गवळी, वय ३४ वर्ष, व्यवसाय ड्रायव्हर, रा.संभाजी चौक, नांदेड असे सांगितले. तेथे थोड्या वेळातच महामार्ग सुरक्षा पथकाचे कर्मचारी व १०८ क्रमांकाची ॲंब्युलन्स आली असता त्या ॲंब्युलन्समध्ये जखमी झालेले दोघांना पण मी व माझे सोबत असलेले माधव भिमराव चव्हाण व घटनास्थळी जमलेले राजाराम किशनराव कानोडे, तुकाराम रामजी साखरे, सचिन येवले असे मिळून जखमींना सदरचे ॲंब्युलन्समध्ये झोपवून सरकारी दवाखाना, नांदेड येथे उपचारासाठी घेऊन गेलो. तेथे उपचारा दरम्यान डॉक्टरांनी दोघांनापण तपासून जखमी पैकी साहेबराव किशनराव कानोडे यांना मृत घोषित केले व संभाजी लक्ष्मण कदम यांचा उपचारा दरम्यान दुपारी मरण पावला असल्याचे डॉक्टरांनी सांगितले. मयत दोघांचे प्रेतावर पी.एम. करून प्रेत अंत्यविधीसाठी त्याचे नातेवाईकाचे ताब्यात दिले. मी काल घटनाघडल्यापासून ते अंत्यविधीपर्यंत मयत साहेबराव किशनराव कानोडे यांचे नातेवाईकासोबत होतो. त्यामुळे काल पो.स्टे.अर्धापुर येथे फिर्याद देऊ शकलो नाही.


तरी यातील ट्रक क्रमांक MH-२६/AD-८७६० चे चालक नामे रामराव गंगाराम गवळी, वय ३४ वर्ष, रा.संभाजी चौक, नांदेड याने आपले ताब्यातील वाहन भरधाव वेगात व हयगयीने चालवून मोटार सायकल क्रमांक MH-२६/P-३०१८ ला जोराची धडक देऊन मोटार सायकलवर असलेले १) साहेबराव किशनराव कानोडे, वय ४० वर्ष, रा.कृष्णानगर, अर्धापुर २) संभाजी लक्ष्मण कदम, वय ४५ वर्ष, रा. रोडगी ता.हादगाव यांना गंभीर जखमी करून त्यांचे मरणांस कारणीभूत झाला आहे. तरी त्यांचे वर योग्य ती कायदेशीर कार्यवाही व्हावी. ही नम्र विनंती.

सदरचा जबाब माझे सांगणे वरून संगणकावर टंकलिखित केला तो मी वाचून पाहिले असता माझे सांगणे प्रमाणे बरोबर व खरा आहे.

समक्ष


ठाणे अंमलदार
पोलीस ठाणे, अर्धापुर

हा जबाब दिला सही



दि. 12/10/2017
52710 - 18 वेळ
1308 वाजारा
भाज 1 ते 5
3302 नं. 1273/17
रुडगी 274,
304 (CA)
आ.प.ची प्रमाणे
दाखल करणे
शुध्द तपास
मा.पो. जि.ना.
मात्रे ओडोशन
पो.उप.जि.
जागोदक
के देखाव
आता आहे
B. M. S.
ठाणे अंमलदार
पोलीस ठाणे, अर्धापुर

CRIME DETAILS FORM

घटनास्थळाचा पंचनामा/गुन्ह्याचा तपसील नमुना

1. राज्य-महाराष्ट्र, जिल्हा-नांदेड, पोलीस स्टेशन अर्धापुर, स्टेशन क्र. 21 / 2017 दिनांक 11 / 10 / 2017

2. अधिनियम व कलम :- अपघात

3. घटनेचे ठिकाण दाखविण्याचे :-

नांव :- सुशेखा साखरे वडीलाचे/पतीचे नांव :- विश्वावर साखरे
 वय 33 वर्ष, धंदा :- शेती जात :- मोबाईल नंबर :- 9970022700
 रा. - अर्धापुर तालुका अर्धापुर जिल्हा नांदेड राज्य महाराष्ट्र

4. गुन्ह्याचा प्रकार (गुन्ह्याचे सर्व पध्दतीसह) :-

i) प्रधान शिर्ष :- स्वतःचे लाव्यालील वाहन दहशेई, निष्काळजीपणे
 ii) प्रधान शिर्षचे वर्गीकरण :- चालवून अपघात होऊन मरणास कारण
 iii) पध्दती :- स्वतःचे लाव्यालील वाहन भरघाव वेगाने
 दहशेई, निष्काळजी पणे चालवून अपघात होऊन दोन
 व्यक्तींचा मरणास कारण

iv) वापरलेली वाहणे :- ट्रक MAT 26 - A 8760

v) केलेले वेषांतर/केलेली बतावणी :-

vi) वापरलेली भाषा/बोली भाषा :-

vii) विशेष वैशिष्ट्य-1 :-

विशेष वैशिष्ट्य-2 :-

विशेष वैशिष्ट्य-3 :-

viii) घटनेच्या ठिकाणाचा प्रकार :- अर्धापुर ते वार्गा जंजारा राष्ट्रीय महामार्ग
 क्र 161 वर अर्धापुर पासून उत्तरेस अंदाजे 3 कि.मी.
 वर पारडी गिऱाराल स्वतंत्रता सेनानी पेट्रोलपंपा जवळ

1) ----- 2) -----

3) ----- 4) -----

आम्ही धंद्याकरांची धरणी झाली. धंद्याकरांचे PSZ डी.के. जातोद्वारा व अर्धापुर येथील सुरेश विश्वाकर साखरे हे धरणी आहेत.

सुरेश विश्वाकर साखरे यांनी धंद्याकरांच्या धंद्याची सोडवणीत एकिकृत सांगून धंद्याकरांचे दाखविले. सर्वत्र धंद्याकरांचे हे वारंगी ते अर्धापुर या गावांमध्ये जाणारा राक्षस महासागरी क 161 हा आहे. अर्धापुर पासून इल्हेस अंदाजे 3 कि.मी अंतरावर असलेल्या स्वतंत्रता येनांनी पेट्रोलपंपासमोरील महासागरीय आहे. धंद्याकरांचे मोटारसायकल व मोटारसायकलांचे अपघातमध्ये नुसलेले पाटे पडलेले दिसत आहेत. सर्वत्र महासागरी हा 60 फुटांचा असून महासागरी डोल्फायसु आहे. डोल्फायसु जवळच मोटार सायकलांचे नुसलेले पाटे, जखमी व्यक्तींचा पाशातील चपखल, डोंबरी रोडवर रक्तचें काढलेले चेंब दिसत आहेत.

धंद्याकरांच्या चतुःसिमा पाहता पुर्वेस :- पय्यु भिम्बाव देवामुख झ. पाडी ता. अर्धापुर यांचे शेत व शेतात आखाडा दिसत आहे.

पश्चिमेस :- स्वतंत्रता येनांनी पेट्रोलपंप दिसत आहे.

दक्षिणेस :- अर्धापुरकडे जाणारा राक्षस महासागरी क 161 आहे

इत्थरेस :- वारंगीकडे जाणारा राक्षस महासागरी क 161 आहे.

अशा प्रकारच्या धंद्याकरांच्या चतुःसिमा असून धंद्याकरांचे वारंगीत वापरलेले ट्रक क्र. MH26 A 58760 हे पंचासप्तहा जल करघ्यात आले.

सर्वत्र धंद्याकरांचे पंचनामा सर्वत्र मुर्ते प्रकाशात आज दि. 11/10/2017 रोजी 1530 वाजता मुक्त करून 1600 वाजता संपविला. तो दिवसा परिशिष्टी प्रमाणे वरील व खाली आहे.

5. बळीचा तपशील (अवश्यक असल्यास स्वतंत्र कागद जोडावा) :-

| अ. क्र. | संपूर्ण नांव | जन्म तारीख / वय | लिंग | राष्ट्रीयत्व | धर्म | जाती/ जमाती | व्यवसाय | पत्ता | दुखाप त गंभीर/ साधी | साधने / हत्यार |
|---------|--------------------------|-----------------|-------|--------------|-------|-------------|--|---|---------------------|----------------|
| 1 | 2 | 3 | 4 | 5 | 6 | 7 | 8 | 9 | 10 | 11 |
| 1 | संभाजी लक्ष्मण कदम | वय 42 वर्षे | पुरुष | भारतीय | हिंदू | मजुरी | श. रोडगा सा. हदगाव जि. नांदेड ड. मु. अर्धापूर | गंभीर डुखापत डुखापत दरमहाक मृत्यू | | |
| 2 | साहेबराव किरानराव कानोडे | वय 40 वर्षे | पुरुष | भारतीय | हिंदू | मजुरी | ग. अर्धापूर सा. अर्धापूर जि. नांदेड | गंभीर डुखापत डुखापत दरमहाक मृत्यू | | |

6. गुन्ह्याचा हेतु :- स्वतःच्या ताब्यातील वाहण ट्रक अडवून वेगाने व हदगावने चालवून अडवून घेऊन दोन व्यक्तींच्या मारणास करणु

7. चोरीच्या/अतंभूत मालमत्तेचा तपशील :-

8. घटनेच्या जागेचे वर्णन :-

आम्हा पंचास P.S. डी. के. जामोदकर पो. व्हे अर्धापूर यांनी कळविले कि अर्धापूर ते वारंगा रोडवर म्हामार्ग क्र 161 वर पारडी शिवासात स्वतंत्र सेनाली पेट्रोलपंपाजवळ अर्धापूर पासून अंदाजे अंतर 3 कि. मी. येथे आज दि. 11/10/2017 रोजी दुपारी 1300 वाजताचे सुमारास वारंगा ते अर्धापूर येणारा एक ट्रक क्र. MH26 AD8760 च्या चालकाने आपल्या ताब्यातील वाहण अडवून वेगाने व हदगाव निष्काळजीपणे चालवून पुढे जाणाऱ्या मोटार साधकाला क्र. MH26 P3018 हिंस जेरीने धडक देऊन त्यावरील दोघेजण गंभीर जखमी झाले आहेत. तरी अदर ठिकाणचा घटनास्थळ पंचनामा करणे काही आपण पंच म्हणून हजेर राहोवे. असे कळविल्याने /Continue

MUPM NO. 914/17 C. M. 67 e.
Date - 11/10/17

Memorandum of a post-mortem examination held at Dr. S. C. G. Nanded Dispensary Hospital

Sambhajji Laxman
on the dead body of Kadam of Village Rodagi
City

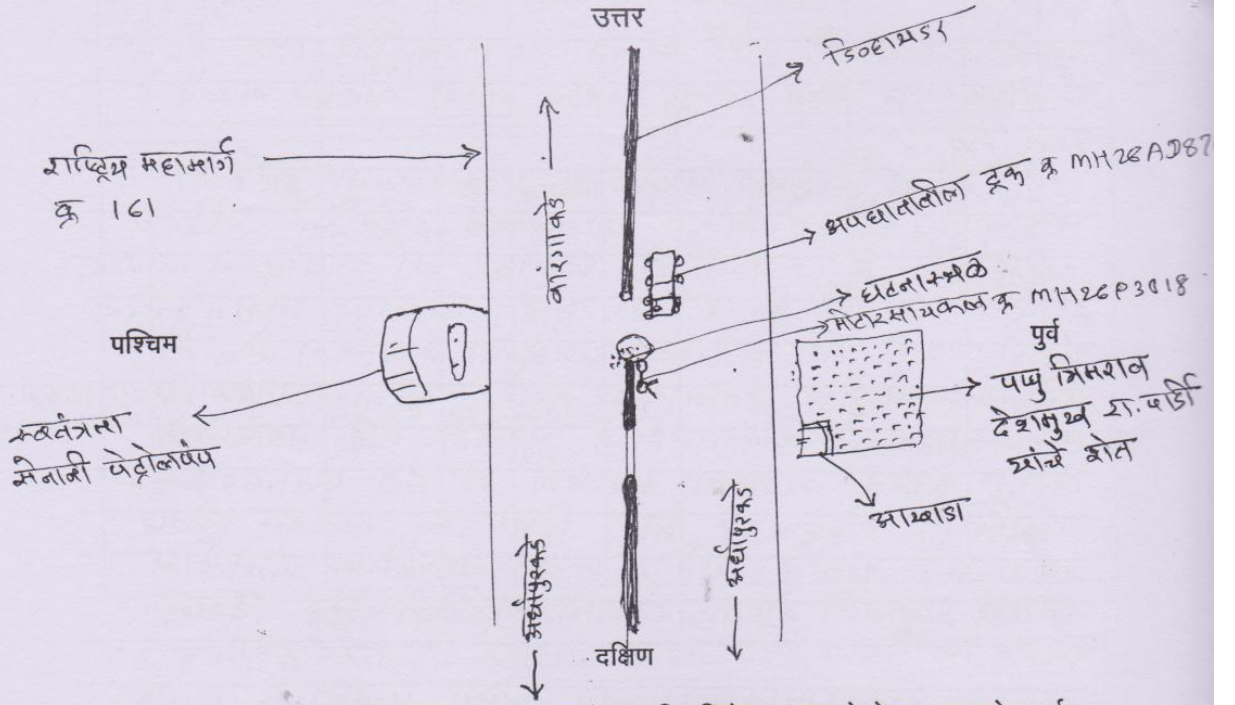
Taluka Hadgaon, District, by Dr. S. V. Kadam

I. General Particulars—

1. (a) By whom was the corpse sent? P.H.C. Ghodke B. No. 1695
P.S. Nanded Gramin.
- (b) Name of place from which sent. } Casualty
Dr. S. C. G. Nanded
- (c) Distance of place from which sent.
2. By whom was the corpse brought? } P.C. Nagargoje B No. 1272
P.S. Nanded Gramin.
3. By whom identified?
4. The date, hour and minute of its receipt. on 11/10/17 at 5.25 PM
- (a) The date, hour and minute of beginning post-mortem examination. on 11/10/17 at 6.45 PM
- (b) The date, hour and minute of ending post-mortem examination. on 11/10/17 at 7.45 PM
5. Substance of accompanying Report from Police Officer or Magistrate, together with the date of death if known. Supposed cause of death or reason, for examination. AS per police inquest and requisition,
Date of death - 11/10/17.
Supposed cause of death - Accident

पोलीस स्टेशन अर्धापूर
आयक क्र. 2157/2017
दिनांक : 15 11/20 17

9. घटनास्थळाचा नकाशा :-



10. तपासकामी प्रत्यक्ष पुरावा म्हणुन गुन्ह्याचे जागेवरून मिळविलेल्या /जप्त केलेल्या मालमत्तेच वर्णन :-

एक TATA 3118 ट कंपनीचा 12 टायरचा जशाचा क्र
MH28 A28760 क्रमांकाचा जुगा ट्रक क्रिमत रुंदीने
5,00,000/- रुपये किं रु.

11. घटनास्थळ पंचनाम्याची दि. 11 / 10 / 2017 वेळ 15-30 ते 16-00 वार बुधवार

12. पंचाची नांवे व संपुर्ण पत्ता आणि सही :-

- 1) जीवन मुंजाजी शेवले वय 36 वर्षे
व्यवसाय शेतरी श. दत्त नगर गोंडस ए. म. धर्शापुर
- 2) तुकाराम रामुजी साखरे वय 30 वर्षे
व्यवसाय - शेतरी श. धर्शापुर जि. गोंडस.

[Signature]

[Signature]

दि. 11/10/2017

तपासीक अमलदार दिगंबर केशव जामोदकर
पदनाम पो. उप नि.
पोलीस स्टेशन धर्शापुर

MUPM NO. 914/17 C. M. 67 e.
Date - 11/10/17

Memorandum of a post-mortem examination held at Dr. S. C. Genc Nanded Dispensary Hospital

Sambhaji Laxman
on the dead body of Kadam
Village Rodagi
City

Taluka Hadgaon, District, by Dr. S. V. Kadam

I. General Particulars—

1. (a) By whom was the corpse sent? P.H.C. Ghodke B. NO. 1695
P.S. Nanded Gramin.
- (b) Name of place from which sent. } Casualty
Dr. S. C. Genc Nanded
- (c) Distance of place from which sent.
2. By whom was the corpse brought? } P.C. Nagargeje B NO. 1272
P.S. Nanded Gramin.
3. By whom identified?
4. The date, hour and minute of its receipt. on 11/10/17 at 5.25 PM
- (a) The date, hour and minute of beginning post-mortem examination. on 11/10/17 at 6.45 PM
- (b) The date, hour and minute of ending post-mortem examination. on 11/10/17 at 7.45 PM
5. Substance of accompanying Report from Police Officer or Magistrate, together with the date of death if known. Supposed cause of death or reason, for examination. AS per police inquest and requisition, Date of death - 11/10/17. Supposed cause of death - Accident

पोलीस स्टेशन अर्घापुर

आवक क्र. 2157/2017

दिनांक: 15/11/2017

10. **Condition of body**—
Whether well-nourished, thin
or emaciated, warm or cold.

Average built, cold.

11. **Rigor Mortis**—Well-marked,
slight or absent; whether
present in the whole body or
part only.

well developed, in all parts of body,

12. Extent and signs of decom-
position, presence post-
mortem lividity of buttocks,
loins, back and thighs or any
other part. Whether bullae
present and the nature of
their contained fluid.
Condition of the cuticle.

No signs of decomposition.

Postmortem lividity present on
posterior aspect of body except
pressure areas, not fixed.

13. **Features**—Whether natural
or swollen, state of eyes,
position of tongue; nature of
fluid (if any) oozing from
mouth, nostrils or ears.

→ Features - Natural.

Eyes - closed, cornea - Hazy

Mouth - closed.

Tongue - inside mouth.

No oozing from mouth, nostrils and
ears.

14. **Condition of skin**—Marks
of blood etc. In suspected
drowning the presence or
absence of cutis anserina
to be noted.

→ Dry & pale.

Dried blood stains present on
both lower limbs.

6. If not examined at Dispensary or Hospital—

(a) Name of place where examined.

(b) Distance from Dispensary or Hospital—

(c) Reason why the body was not sent to the Dispensary or Hospital.

not applicable.

II. External Examination—

7. Sex, apparent age, race or caste.

male, 42 years.

Description of clothes and of ornaments on the body.

8. Condition of the clothes— Whether wet with water, stained with blood or soiled with vomit or foecal matter.

9. Special marks on the skin such as scars, tattooing etc., any malformations peculiarities, or other marks of identification. State of the teeth.

→ one grey colour pant, one faint green colour shirt. clothes stained with blood, red waist thread one urinary catheter present in situ, cotton bandages present around scrotum and inguinal region soaked in blood.

Handed over to PC on duty.

Body identified by PC on duty. Teeth - intact

In newly born infants, the length and (if possible), the weight of the body to be recorded together with the state of the hair, nails and umbilical cord, its length, whether placenta is attached or not, if present, its size and condition.

Not applicable.

13.

14. C
o
d
al
fo

III. Internal Examination—

19. Head—

- (i) Injuries under the scalp, Intact, no injury, their nature.
- (ii) **Skull**—Vault and base— Intact, no fracture. describe fractures, their sites, dimensions, directions, etc.
- (iii) **Brain**—The appearance of its coverings, size, weight and general condition of the organ itself and any abnormality found in its examination to be carefully noted (weight M. 3 grams F. 2.75 grams).
 meninges - intact
 Brain - intact, pale congested and oedematous.

20. Thorax—

- (a) Walls, ribs, cartilages Intact, no fracture.
- (b) Pleura Intact, pale.
- (c) Larynx, Trachea and Bronchi: Intact, no foreign body.
- (d) Right Lung } Both lungs intact, pale and oedematous.
- (e) Left Lung }
- (f) Pericardium Intact.
- (g) Heart with weight } Intact, scanty blood present.
- (h) Large vessels }
- (j) Additional remarks. Nil.

Refer to column no (17).

No purging.

→ Straight

15. Injuries to external genitals-
Indication of purging.

1) Sutured wound present on the left eyebrow of length 2cm, with two sutures in situ, on opening size of wound 2cm x 0.5cm x tissue deep, margins irregular, abraded.

16. Position of limbs—
Especially of arms and of fingers in suspected drowning the presence or absence of sand or earth within the nails or on the skin of hands and feet.

2) Contused abrasion present on left malar region of size 2cm x 1cm, red.

3) Lacerated wound present on the right index finger, dorsal aspect, vertically placed of size 2cm x 0.5cm x tissue deep, margins irregular, abraded.

17. Surface wounds and injuries—Their nature, position, dimensions (measured) and directions to be accurately stated—their probable age and causes to be noted.

4) Graze abrasion present on the left leg and left knee joint, anterolateral aspect of size 22cm x 7cm, directed upward, red.

If bruises be present what is the condition of the subcutaneous tissues?

5) Contused abrasion present on the left ankle joint, lateral aspect of size 10cm x 3cm, red.

(N.B.—(When injuries are numerous and cannot be mentioned within the space available they should be mentioned on a separate paper which should be signed).

6) Lacerated wound present on right side of groin, perineal and left side of thigh, obliquely placed of size 16cm x 5cm x bone deep, underlying pubic bone fractured, left pubic ramus fractured into pieces, underlying muscles, vessels, nerves, lacerated, blood oozing out, margins irregular, right testis exposing exterior.

18. Other injuries discovered by external examination or palpation as fractures etc.

7) Contused abrasion present on the right leg, in middle third part of size 4cm x 2cm, red.

Refer to injury No. (6),
from column no (17)

8) Contused abrasion present on the left flank region iliac region of size 10cm x 3cm, red.

9) Contused abrasion present on the left gluteal region, anteriolateral aspect of size 2cm x 1cm, red.

(a) Can you say definitely that the injuries shown against serial Nos. 17 and 18 are ante mortem injuries?

10) Multiple contused abrasions present left foot dorsal aspect, involving toes of sizes 2cm x 0.5cm, 1cm x 0.5cm, 0.5cm x 0.5cm, red.

22. *Spine and Spinal Cord— intact, not opened.

Opinion as to the cause
probable cause of death.

“Haemorrhagic shock due to
injury to pelvis.”

स. व. कादम
(Dr. S. V. Kadam)

Resident
Dept. of Forensic Medicine
Dr. S.C.G. & C. Vishnupur
Nanded-431608.

Dated 11/10/19-200

(Signature)

*The Spinal Cord need not be examined unless there are any indications of disease, Strychnia poisoning or injury.

Note—The report must be written and signed immediately after the examination. Medical Officers will at once despatch a duplicate copy to the Civil Surgeon of their district for record in his office.

Great care should be taken not to cut the viscera before they have been inspected *in situ*.

21. Abdomen—

Walls Intact

Peritoneum } Intact About 1.5 litre of blood present.

Cavity }

Buccal Cavity, teeth, tongue and Pharynx. Intact, no foreign body.

Desophagus Intact

Stomach and its contents } Intact, 100ml semidigested food present, no abnormal smell perceived.

Small intestine and its contents. } Intact, partly loaded with faeces and gases.

Large intestine and its contents. }

Liver (with weight) and gall bladder. Intact, pale.

Pancreas and Suprarenals Intact, pale.

Spleen with weight Intact, pale.

Kidneys with weight Intact, pale.

Bladder Intact.

Organs of generations Refer to column no. (17) injury no. (8) eight testis along with its covering exposing to exterior.

Additional remarks with where possible, medical officer's deduction from the state of the contents of the stomach as to time of death and last meal. Nil

Re
son

State which viscera (if any) have been retained for chemical examination and also quote the numbers on the bottles containing the same. Viscera not preserved.

Drum No. 912/17

Date - 11/10/17

Memorandum of a post-mortem examination held at Dr. S.C. Umc Nanded Dispensary Hospital

Sahebrao Sp Kishanrao
on the dead body of Kanode
Village of Krishnanagar, Ardhapur
City

Taluka Ardhapur, District Nanded, by Dr. S.V. Kadam

I. General Particulars—

1. (a) By whom was the corpse sent?

P.H.C. Ghodke B.No. 1695
P.S. Nanded Gramin.

(b) Name of place from which sent.

casualty
Dr. S.C. Umc Nanded.

(c) Distance of place from which sent.

2. By whom was the corpse brought?

P.C. Nagargeje B.No. 1272
P.S. Nanded Gramin.

3. By whom identified?

4. The date, hour and minute of its receipt.

on 11/10/17 at 4:20 pm

(a) The date, hour and minute of beginning post-mortem examination.

on 11/10/17 at 4:45 pm

(b) The date, hour and minute of ending post-mortem examination.

on 11/10/17 at 5:45 pm

5. Substance of accompanying Report from Police Officer or Magistrate, together with the date of death if known. Supposed cause of death or reason, for examination.

As per police inquest and requisition, deceased had road accident on date - 11/10/17, admitted in Dr. S.C. Umc Nanded where he declared brought dead.
Date of death - 11/10/17.

Supposed Cause of death - "Head Injury."

पोलीस स्टेशन अर्धापुर
आपक क्र. 2157/2017

दिनांक: 15/11/2017

Case No. 914/17

200

Date - 11/10/17

Place ^{Dispensary} Dr. S.C. GMC Nanded _{Civil Hospital} 200

Forwarded to the Police Sub-Inspector P.S. Nanded Gramin.

for information with reference to his No. _____ of 200

Viscera has been preserved. It may please be stated *Immediately* whether examination by the Chemical Analyser is necessary or it is to be destroyed.

(Signature)
Dr. S.V. Kadam
Civil Surgeon or M. M. S. Officer
Resident
Dept. of Forensic Medicine
Dr. S.C.G.M.C. Vishnupuri
Nanded-431606

Copy forwarded with compliments to the Civil Surgeon, _____ for information.

M. M. S. Officer

Seen and examined by the Civil Surgeon,

200

on

Remarks of the Civil Surgeon,



(if any)

Civil Surgeon

10. **Condition of body**—
Whether well-nourished, thin
or emaciated, warm or cold.

Average built, cold,

11. **Rigor Mortis**—Well-marked,
slight or absent; whether
present in the whole body or
part only.

well marked, present in the whole
body.

12. Extent and signs of decom-
position, presence post-
mortem lividity of buttocks,
loins, back and thighs or any
other part. Whether bullae
present and the nature of
their contained fluid.
Condition of the cuticle.

no signs of decomposition.
Postmortem lividity present on
posterior aspect of body except
pressure areas, not fixed.

13. **Features**—Whether natural
or swollen, state of eyes,
position of tongue: nature of
fluid (if any) oozing from
mouth, nostrils or ears.

Features - Natural.
Eyes - closed, cornea - Hazy
mouth - closed.
Tongue - inside mouth.
No oozing from mouth, nostrils
and ear.

14. **Condition of skin**—Marks
of blood etc. In suspected
drowning the presence or
absence of cutis anserina
to be noted.

Dry, pale.

6. If not examined at Dispensary or Hospital—

- (a) Name of place where examined.
- (b) Distance from Dispensary or Hospital—
- (c) Reason why the body was not sent to the Dispensary or Hospital.

Not applicable.

II. External Examination—

7. Sex, apparent age, race or caste.

male, 40 years

Description of clothes and of ornaments on the body.

one jeans pant with black belt
one full sleeve shirt torn at places, red waist thread, one underswear, one baniyan.

8. Condition of the clothes— Whether wet with water, stained with blood or soiled with vomit or foecal matter.

Intact, handed over to PE on duty.

9. Special marks on the skin such as scars, tattooing etc., any malformations peculiarities, or other marks of identification. State of the teeth.

Body identified by PE on duty. Teeth - intact.

In newly born infants, the length and (if possible), the weight of the body to be recorded together with the state of the hair, nails and umbilical cord, its length, whether placenta is attached or not, if present, its size and condition.

NOT applicable.

III. Internal Examination—

19. Head—

- (i) Injuries under the scalp, their nature. **Intact, no injury.**
- (ii) **Skull**—Vault and base—describe fractures, their sites, dimensions, directions, etc. **Intact, no fracture.**
- (iii) **Brain**—The appearance of its coverings, size, weight and general condition of the organ itself and any abnormality found in its examination to be carefully noted (weight M. 3 grams F. 2.75 grams). **Meninges - intact.**
Brain - intact, pale, oedematous.

20. Thorax—

- (a) Walls, ribs, cartilages **Intact, fracture of 3rd and 4th rib on right side, in midaxillary line, and fracture of 2nd to 10th rib on left side in midaxillary line, with extravasation of blood in intercostal muscles. fracture margins irregular infiltrated with blood.**
- (b) Pleura **Torn at corresponding to fracture of ribs on both sides, with 300ml of blood present in left pleural cavity.**
- (c) Larynx, Trachea and Bronchi **Intact, no foreign body.**
- (d) Right Lung **Intact, pale, oedematous.**
- (e) Left Lung **pale, oedematous with multiple contusions and laceration present on lateral surface of lung.**
- (f) Pericardium **Intact.**
- (g) Heart with weight
- (h) Large vessels **Intact, blood and blood clots present.**
- (i) Additional remarks. **Nil.**

15. Injuries to external genitalia.
Indication of purging.

→ No injury.
No purging.

16. **Position of limbs**—
Especially of arms and
of fingers in suspected
drowning the presence or
absence of sand or earth
within the nails or on the
skin of hands and feet.

→ straight.

17. **Surface wounds and
injuries**—Their nature, posi-
tion, dimensions (measured)
and directions to be
accurately stated—their
probable age and causes
to be noted.

1) Lacerated wound present on
left maxillary region of size $2\text{cm} \times$
 $1\text{cm} \times$ tissue deep, obliquely placed.

2) Contused abrasion present on
left maxillary region of size $4\text{cm} \times 3\text{cm}$
red.

3) Lacerated wound present on
the chin, on right side of size
 $1\text{cm} \times 0.5\text{cm} \times$ tissue deep.

If bruises be present what is
the condition of the
subcutaneous tissues?

4) Graze abrasion present on the
left shoulder of size $3\text{cm} \times 2\text{cm}$, red,
directed upward.

5) Multiple contused abrasions present
on the right hand, dorsal aspect
of size $1\text{cm} \times 0.5\text{cm}$, $0.7\text{cm} \times 0.5\text{cm}$,
 $0.5\text{cm} \times 0.5\text{cm}$, red.

6) Contused abrasion present on
left side of chest, 5cm above the
nipple of size $1\text{cm} \times 0.7\text{cm}$, red.

(N.B.—(When injuries are
numerous and cannot be
mentioned within the space
available they should be
mentioned on a separate
paper which should be
signed).

7) Abrasion present on the left
side of chest wall infra axillary
region, 15cm below axilla of size
 $1\text{cm} \times 1\text{cm}$, red.

8) Lacerated wound present on
the right heel posteromedial
aspect of size $10\text{cm} \times 4\text{cm} \times$ through
and through, with exposing underlying
bones to exterior; margins irregular

18. Other injuries discovered by
external examination or
palpation as fractures etc.

↓
no fracture.

9) Contused abrasion present on
right elbow, lateral aspect of size
 $1\text{cm} \times 1\text{cm}$, red.

(a) Can you say definitely
that the injuries shown
against serial Nos. 17
and 18 are ante mortem
injuries?

→ yes, Antemortem injuries.

III. Internal Examination—

19. Head—

- (i) Injuries under the scalp, their nature. **Intact, no injury.**
- (ii) **Skull**—Vault and base—describe fractures, their sites, dimensions, directions, etc. **Intact, no fracture.**
- (iii) **Brain**—The appearance of its coverings, size, weight and general condition of the organ itself and any abnormality found in its examination to be carefully noted (weight M. 3 grams F. 2.75 grams). **Meninges - intact.**
Brain - intact, pale, oedematous.


20. Thorax—

- (a) Walls, ribs, cartilages **Intact, fracture of 3rd and 4th rib on right side, in midaxillary line, and fracture of 2nd to 10th rib on left side in midaxillary line, with extravasation of blood in intercostal muscles. fracture margins irregular infiltrated with blood.**
- (b) Pleura **Torn at** corresponding to fracture of ribs on both sides, with **300ml** of blood present in left pleural cavity.
- (c) Larynx, Trachea and Bronchi. **Intact, no foreign body.**
- (d) Right Lung **Intact, pale, oedematous.**
- (e) Left Lung **pale, oedematous with multiple contusions and laceration present on lateral surface of lung.**
- (f) Pericardium **Intact.**
- (g) Heart with weight
- (h) Large vessels **Intact, blood and blood clots present.**
- (i) Additional remarks. **Nil.**

22. *Spine and Spinal Cord— Intact, not opened.

Opinion as to the cause of probable cause of death.

Blunt trauma to chest and abdomen."



Signature
(Dr. S.V. Kadam)

Resident
Dept. of Forensic Medicine
Dr. S.C.G. V.C. Vishnupuri
Manded-431609

Dated 11/10/17 200

(Signature)

*The Spinal Cord need not be examined unless there are any indications of disease, Strychnia poisoning or injury.

Note—The report must be written and signed immediately after the examination. Medical Officers will at once despatch a duplicate copy to the Civil Surgeon of their district for record in his office.

Great care should be taken not to cut the viscera before they have been inspected *in situ*.

21. Abdomen—

Walls Intact .

Peritoneum } one litre of blood present.

Cavity }

Buccal Cavity, teeth, tongue and Pharynx. Intact, no foreign body.

Desophagus Intact.

Stomach and its contents } Intact, 100ml semidigested food present, no abnormal smell perceived.

Small intestine and its contents. }

Large intestine and its contents. } Intact, partly loaded with faeces and gases.

Liver (with weight) and gall bladder. ^{small} Intact. Lower part of right lobe of liver lacerated into pieces, parenchyma deep, surrounded by blood clot, pale.

Pancreas and Suprarenals Intact, pale .

Spleen with weight Intact, pale .

Kidneys with weight Intact, pale .

Bladder Intact, empty

Organs of generations Intact .

Additional remarks with → Nil
 where possible, medical officer's deduction from the state of the contents of the stomach as to time of death and last meal.

State which viscera (if any) Viscera not preserved,
 have been retained for chemical examination and also quote the numbers on the bottles containing the same.

M.P.M. No. 912/17

200

Date - 11/10/17

Place Dispensary
Civil Hospital

Dr. S.C. Crane Nanded 200

Forwarded to the Police Sub-Inspector P.S. Nanded Gramin.

for information with reference to his No.

of

200

Viscera has been preserved. It may please be stated *immediately* whether examination by the Chemical Analyser is necessary or it is to be destroyed.

S.V.K.

Dr. S.V. Kadans
Civil Surgeon or M.M.S. Officer

Residents
Dept. of Forensic Medicine
Dr. S.C.G.M.C. Vishnupuri
Nanded-431606.

Copy forwarded with compliments to the Civil Surgeon,

for information.

M. M. S. Officer


Seen and examined by the Civil Surgeon,

200

on

Remarks of the Civil Surgeon,

(if any)



Civil Surgeon