

## FORM COMP AA

(sec Rules 253 (c) 254 (c) (iii), 254 (80 255 (1) (iv))

### REPORT ABOUT THE MOTOR VEHICLES ACCIDENTS

1	Name of the Police Station	Police Station Ardhapur
2	CR.NO./TAR No./SDE No.	273/2017 U/S 279,304(A)I P C
3	Date, Time and Place of the accident.	11/10/2017 at 1300 hrs. Nanded to Hingoli road Pardi tq.Ardhapur
4	Name of the Injured / Deceased	Sahebrao Kishan Kanode age 35 year R/o Krushnanagar Ardhapur
5	Name of Hospital to Which he/she was removed	Govt.Hospital Nanded
6	Number of vehicles and type of the vehicle	MH 26 -AD- 8760 Truck
7	Name and address of the Driver of the vehicle with particulars or Driving License of the said Driver and the address of the Issuing Authority of the said Driving License. The number of Badge in case of Public Service Vehicle and the address of the Issuing Authority of the said Badge.	Ramrao Gangaram Gavle age 34 year R/o Sambhajichok Nanded MH 26 - 6056200705 RTO Nanded
8	Name and Address of the Owner of the vehicle as it stands on the date of the accident.	Santosh Suryanarayan Amilkantwar R/o Mugat tq.Mudkhed Nanded
9	Name and address of the insurance Company with whom the vehicle was insured and the Divisional office of the said insurance Company.	United India Insurance Comp. Ltd.Nanded
10	Number of Insurance Policy/Insurance Certificate and the date of Validity of the insurance Policy/Insurance Certificate.	2306003116/109708265 21/10/2017
11	Action taken if any and the result there of	An offences has been registered against the accuse and Investigation is going on.

Inspector of Police  
Police Station Ardhapur



फिर्याद

दि. १२/१०/२०१७

मी सुरेश विश्वांबर साखरे वय ३३ वर्ष व्यवसाय-शेती रा.गणपुर ता.अर्धापुर जि.नांदेड हल्ली मुक्काम कृष्णानगर अर्धापुर ता.अर्धापुर जि.नांदेड, मो.नं. - ९९७००२२७००


समक्ष पो.स्टे.अर्धापुर येथे येवून जबाब देतो कि मी वरील प्रमाणे राहणारा असुन शेती व एल. आय.सी.एजंट व्यवसाय करतो.काल दि.११/१०/२०१७ रोजी दुपारी ०१.०० वाजताचे दरम्यान मी व माझा मित्र माधव भिमराव चव्हाण वय ४० वर्ष व्यवसाय-टेलर रा.अर्धापुर असे दोघे जण माझ्या मोटारसायकलमध्ये पेट्रोल भरण्यासाठी मोटारसायकल घेवून अर्धापुर ते वारंगगा रोडवर स्वातंत्र सेनानी पेट्रोलपंपावर जात असतांना पेट्रोलपंपाचे जवळ आमचे समोरून वारंगगाकडुन अर्धापुरच्या दिशेन एक ट्रक त्याचा क्रमांक MH-२६/AD-८७६० हा भरधाव वेगाने येत होती. एक मोटार सायकल क्रमांक MH-२६/P-३०१८ ही सुध्दा वारंगगाकडुन अर्धापुरचे दिशेने येत असतांना ट्रकचा वेग मर्यादपेक्षा जास्त असल्याने ट्रक चालकाने मोटार सायकलला पाठीमागुन धडक दिली. मोटार सायकलवर दोन इसम मोटार सायकल सह जोरात डिव्हायडरला आदळुन बाजुला पडले व त्यांना गंभीर दुखापत झाली. आम्ही दोघे जन ताबडतोब त्या दोघांचे जवळ गेलो व त्यांना उठवुन बसविले. मी त्या जखमी असलेल्या दोघांनाही चांगल्या प्रकारे ओळखतो. जखमी पैकी एक जन साहेबराव किशनराव कानोडे हे आमचे गावातील व आमचे नात्यातीलच आहेत. तर दुसरा जखमी ईसम संभाजी लक्ष्मण कदम हा रोडगी ता.हादगाव येथील असुन तो साहेबराव चा मित्र असल्यामुळे नेहमी आमचे गावात जात व येत असतो आणि तो सध्या अर्धापुर येथेच किरायाने राहत होता.

आम्ही ट्रक चालकास नांव, गाव विचारले असता त्याने त्याचे नांव रामराव गंगाराम गवळी, वय ३४ वर्ष, व्यवसाय झायव्हर, रा.संभाजी चौक, नांदेड असे सांगितले. तेथे थोडया वेळातच महामार्ग सुरक्षा पथकाचे कर्मचारी व १०८ क्रमांकाची ॲंब्युलन्स आली असता त्या ॲंब्युलन्समध्ये जखमी झालेले दोघांना पण मी व माझे सोबत असलेले माधव भिमराव चव्हाण व घटनास्थळी जमलेले राजाराम किशनराव कानोडे, तुकाराम रामजी साखरे, सचिन येवले असे मिळुन जखमींना सदरचे ॲंब्युलन्समध्ये झोपवुन सरकारी दवाखाना, नांदेड येथे उपचारासाठी घेऊन गेलो. तेथे उपचारा दरम्यान डॉक्टरांनी दोघांनापण तपासुन जखमी पैकी साहेबराव किशनराव कानोडे यांना मृत घोषित केले व संभाजी लक्ष्मण कदम यांचा उपचारा दरम्यान दुपारी मरण पावला असल्याचे डॉक्टरांनी सांगितले. मयत दोघांचे प्रेतावर पी.एम. करुन प्रेत अंत्यविधीसाठी त्याचे नातेवाईकाचे ताब्यात दिले. मी काल घटनाघडल्यापासुन ते अंत्यविधीपर्यंत मयत साहेबराव किशनराव कानोडे यांचे नातेवाईकासोबत होतो. त्यामुळे काल पो.स्टे.अर्धापुर येथे फिर्याद देऊ शकलो नाही.


तरी यातील ट्रक क्रमांक MH-२६/AD-८७६० चे चालक नामे रामराव गंगाराम गवळी, वय ३४ वर्ष, रा.संभाजी चौक, नांदेड याने आपले ताब्यातील वाहन भरधाव वेगात व हयगयीने चालवुन मोटार सायकल क्रमांक MH-२६/P-३०१८ ला जोराची धडक देऊन मोटार सायकलवर असलेले १) साहेबराव किशनराव कानोडे, वय ४० वर्ष, रा.कृष्णानगर, अर्धापुर २) संभाजी लक्ष्मण कदम, वय ४५ वर्ष, रा. रोडगी ता.हादगाव यांना गंभीर जखमी करुन त्यांचे मरणांस कारणीभुत झाला आहे. तरी त्यांचे वर योग्य ती कायदेशीर कार्यवाही व्हावी. ही नम्र विनंती.

सदरचा जबाब माझे सांगणे वरुन संगणकावर टंकलिखित केला तो मी वाचुन पाहिले असता माझे सांगणे प्रमाणे बरोबर व खरा आहे.

समक्ष

  
ठाणे अंमलदार  
पोलीस ठाणे, अर्धापुर

हा जबाब दिला सही



दि. 12/10/2017  
50750.18 वेळ  
1308 वाजता  
भाज 1 ते 5  
3302 नं. 273/17  
पुढे 274,  
304 (A)  
आ. ५ ची प्रती  
दाखल करणे  
पुढील लाम  
मा.पो. जि.ना.  
मात्रे आदेशाने  
पो.उप.जि. यांचे  
जाणोदकर यांचे  
के देण्यात  
आता आहे  
B. M. M.  
ठाणे अंमलदार  
पोलीस ठाणे, अर्धापुर



## CRIME DETAILS FORM

घटनास्थळाचा पंचनामा/गुन्ह्याचा तपसील नमुना

1. राज्य-महाराष्ट्र, जिल्हा-नांदेड, पोलीस स्टेशन अर्धापूर, जे.डी. नोंद नं. अर्धापूर प्रहरी खबर/कार्यवाही क्र. 21 /2017 दिनांक 11/10/2017

2. अधिनियम व कलम :- अप्रत्यात

3. घटनेचे ठिकाण दाखविण्याचे :-

नांव :- सुरेश साधु

वडीलाचे/पतीचे नांव :- विठ्ठल साधु

वय 33 वर्ष, धंदा :- शेती

जात :- मोबाईल नंबर :- 9970022700

रा. अर्धापूर

तालुका अर्धापूर

जिल्हा नांदेड

राज्य महाराष्ट्र

4. गुन्ह्याचा प्रकार (गुन्ह्याचे सर्व पध्दतीसह) :-

i) प्रधान शिर्ष :-

स्वतःचे ताब्यातील दाह एथेगर्ड, निष्काळीपाने चालवून अप्रत्यात होऊन मरणास कारण.

ii) प्रधान शिर्षचे वर्गीकरण

स्वतःचे ताब्यातील दाह प्ररक्षा वेगळे

iii) पध्दती

एथेगर्ड, निष्काळीपाने चालवून अप्रत्यात होऊन वेगळे व्यक्तीच्या मरणास कारण

iv) वापरलेली वाहणे

ट्रक MAR 26 - A 8760

v) केलेले वेषांतर/केलेली बतावणी :-

vi) वापरलेली भाषा/बोली भाषा :-

vii) विशेष वैशिष्ट्य-1 :-

विशेष वैशिष्ट्य-2 :-

विशेष वैशिष्ट्य-3 :-

viii) घटनेच्या ठिकाणाचा प्रकार

अर्धापूर ते वार्गा जंजारा राष्ट्रीय महामार्ग

ix) अंतर्भूत मालमत्तेचा प्रकार

क्र 161 वर अर्धापूर पासून उत्तरेस अंदाजे 3 कि.मी वर परडी जिवारात स्वतंत्रता सेनानी पेट्रोलपंपा जवळ

1) -----

2) -----

3) -----

4) -----



5. बळीचा तपशील (अवश्यक असल्यास स्वतंत्र कागद जोडावा) :-

अ. क्र.	संपुर्ण नांव	जन्म तारीख / वय	लिंग	राष्ट्रीयत्व	धर्म	जाती/ जमाती	व्यवसाय	पत्ता	दुखाप त गंभीर/ साधी	साध / हत्यार
1	2	3	4	5	6	7	8	9	10	11
1	संभाजी लक्ष्मण कदम	वय 42 वर्ष	पुरुष	भारतीय	हिंदू		मजुरी	श. शेडगा ता. हदगाव जि. नांदेड ड. मु. अर्धापूर	गंभीर दुखापत उपचार दरम्यान मृत्यू	—
2	साहेबराव किरानराव काजोडे	वय 40 वर्ष	पुरुष	भारतीय	हिंदू		मजुरी	श. अर्धापूर ता. अर्धापूर जि. नांदेड	गंभीर दुखापत उपचार दरम्यान मृत्यू	

6. गुन्ह्याचा हेतु :- स्वतःच्या ताब्यातील वाहन टूक करून घ्यावे व शेडगाव व हदगाव येथील चालकाने वाहनात धडन देणे यामुळे घडलेल्या मरणास कारण

7. चोरीच्या/अतंभृत मालमत्तेचा तपशील :-

8. घटनेच्या जागेचे वर्णन :-

आम्हा पॅरास P52 डी. के. जामोदकर पो. व्हे अर्धापूर यांनी कळविले कि अर्धापूर ते वारंगो शेडगाव रस्ता मार्ग क्र 161 वर पारडी शिबारात स्वतःगे सेनानी पेट्रोलपंपाजवळ अर्धापूर पासून अंदाजे अंतर 3 कि. मी. येथे आज दि. 11/10/2017 रोजी दुपारी 1300 वाजताचे कुमारस वारंगो ते अर्धापूर येणारा एक टूक क्र MM26 RD8760 च्या चालकाने आपल्या ताब्यातील वाहन अर्धापूर येणारे व हदगाव निष्काळजीपणाने चालवून पुढे जाण्याच्या मोटार सायकल क्र MM26 P3018 हिंस जेव्हा व्हे घडक देवून त्यावरील दोघेजण गंभीर जखमी झाले आहेत. लगेच मदत ठिकाणचा घटनास्थळ पंचनामा करणे कामी आपण पंच म्हणून हजर राहोवे. असे कळविल्याने /Continue



आम्ही धंद्याकरांची एअर ड्राव्हो. धंद्याकरांचा PSZ डी.के. जातोवका व ~~कि~~ अर्धापूर येथील सुरेश विरवाकर साखरे हे एअर होत.

सुरेश विरवाकर साखरे यांनी धंद्याकरांच्या धंद्याची थोडक्यात एकिकृत सांगुन धंद्याकरांचे दाखविले. सध्याचे धंद्याकरांचे वारंगो ते अर्धापूर या गावांवरून जाणारा राक्षिय महामार्ग क्र 161 हो आहे. अर्धापूर जाणुन इतरस अंदाजे 3 कि.मी अंतरावर प्रसलेल्या स्वतंत्रता सेनानी पेट्रोलपंपासमोरील महामार्गावर आहे. धंद्याकरांचा मोटारसायकल व मोटारसायकलाचे अपघातमध्ये नुटलेले पार्ट पडलेलेले दिसत आहेत. सध्याचा महामार्ग हो 60 फुटाचा अखुन महामार्गी डिव्हाडर आहे. डिव्हाडर जवळ मोटार सायकलाचे नुटलेले पार्ट, जखमी व्यक्तीच्या पायातील चपचप, डांबरी रोडवर रक्तचे काढलेले रेंव दिसत आहेत.

धंद्याकरांच्या चतुःसिमा पाहता पुर्वेस :- पणु भिस्साव वेरामुथु झ. पाडी तो. अर्धापूर यांचे शेेत व शेतात आखाडा दिसत आहे.

पश्चिमेस :- स्वतंत्रता सेनानी पेट्रोलपंप दिसत आहे.

दक्षिणेस :- अर्धापूरकडे जाणारा राक्षिय महामार्ग क्र 161 आहे

उत्तरेस :- वारंगोकडे जाणारा राक्षिय महामार्ग क्र 161 आहे.

अशा प्रकारच्या धंद्याकरांच्या चतुःसिमा अखुन धंद्याकरांचा वरुण गुन्ध्यात वापरलेले ट्रक क्र. MH26 A 98760 हे पंचासप्तहा जप्त करण्यात आले.

सध्या धंद्याकरांचे पंचनामा नव्याचे मुथ प्रकारात आज दि. 11/10/2017 रोजी 1530 वाजता मुक कान 1600 वाजता संपविला. तो दिसल्या परिसिधली प्रमाणे बरोबर व खरा आहे.



MLM NO. 914/17 C. M. 67 e.

Date - 11/10/17

Memorandum of a post-mortem examination held at Dr. S. C. Genc Nanded Dispensary Hospital

Sambhajji Laxman  
on the dead body of Kadam  
Village Rodagi  
City

Taluka Hadgaon, District

by Dr. S. V. Kadam

I. General Particulars—

1. (a) By whom was the corpse sent? P. H. C. Ghodke B. NO. 1695  
P. S. Nanded Gramin.

(b) Name of place from which sent. } Casualty  
Dr. S. C. Genc Nanded

(c) Distance of place from which sent.

2. By whom was the corpse brought? } P. C. Nagargoje B. NO. 1272  
P. S. Nanded Gramin.

3. By whom identified?

4. The date, hour and minute of its receipt. on 11/10/17 at 5.25 PM

(a) The date, hour and minute of beginning post-mortem examination. on 11/10/17 at 6.45 PM

(b) The date, hour and minute of ending post-mortem examination. on 11/10/17 at 7.45 PM

5. Substance of accompanying Report from Police Officer or Magistrate, together with the date of death if known. Supposed cause of death or reason, for examination

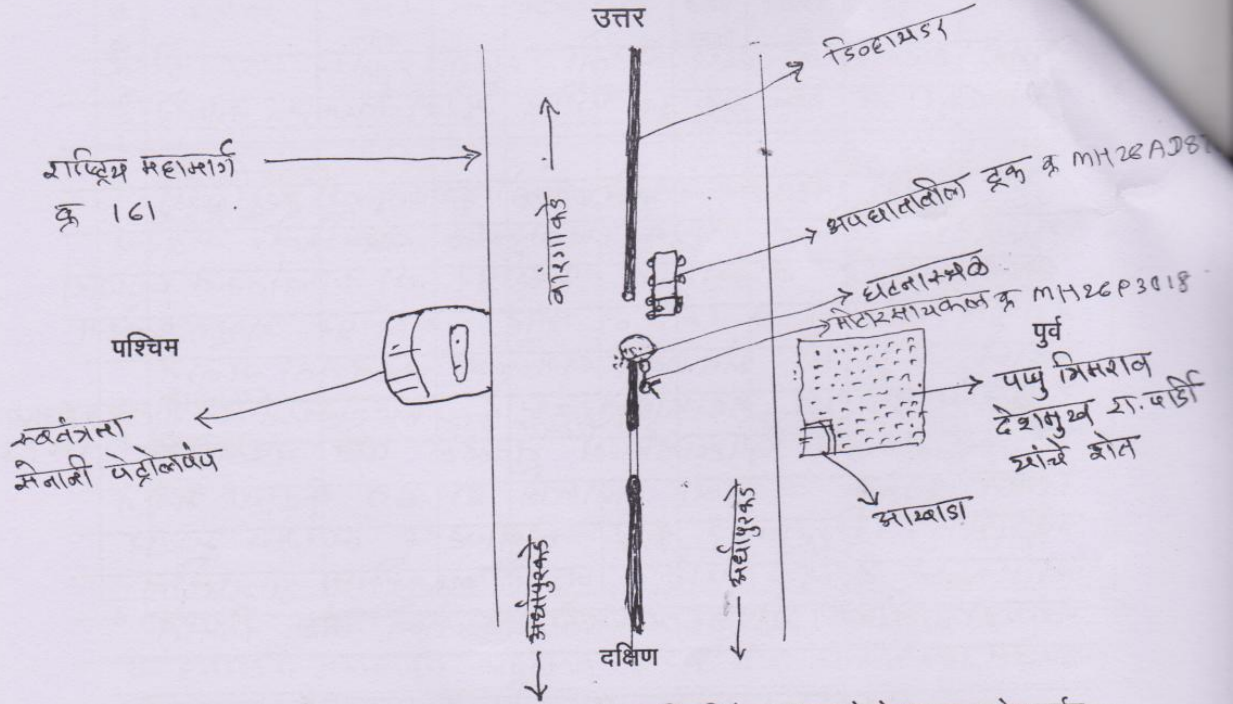
AS per police inquest and requisition,  
Date of death - 11/10/17  
Supposed cause of death - Accident

पोलीस स्टेशन अर्धापूर

आवक क्र. 2157/2017

दिनांक: 15/11/2017

## 9. घटनास्थळाचा नकाशा :-



## 10. तपासकामी प्रत्यक्ष पुरावा म्हणुन गुन्ह्याचे जागेवरुन मिळविलेल्या /जप्त केलेल्या मालमतेचे वर्णन :-

एक TATA 3118 कंपनीचा 12 टायरचा जशाचा क्र  
MH2E AJ8760 क्रमांकाचा जुगा टूक किमान किंदाचे  
5,00,000/- रुपये किं हे.

11. घटनास्थळ पंचनाम्याची दि. 11 / 10 / 2017 वेळ 15-30 ते 16-00 वार बुधवार

12. पंचाची नांवे व संपुर्ण पत्ता आणि सही :-

- 1) जीवन मुंजाजी शेवले वय 36 वर्षे  
व्यवसाय - शेती रा. दत्त नगर नोंद SE. मु. अर्धापुरा
- 2) तुकाराम रामजी साखर वय 30 वर्षे  
व्यवसाय - शेती रा. अर्धापुरा जि. नोंद SE.

July  
[Signature]

[Signature]

दि. 11/10/2017

तपासक अमलदार दिगांबर केशव जासोदकर  
पदनाम पो. उप नि.  
पोलीस स्टेशन अर्धापुरा



Condition of body—  
Whether well-nourished, thin  
emaciated, warm or cold.

Average built, cold.

11. **Rigor Mortis**—Well-marked, slight or absent; whether present in the whole body or part only. well developed, in all parts of body.
12. Extent and signs of decomposition, presence post-mortem lividity of buttocks, loins, back and thighs or any other part. Whether bullae present and the nature of their contained fluid. Condition of the cuticle. No signs of decomposition. Postmortem lividity present on posterior aspect of body, except pressure areas, not fixed.
13. **Features**—Whether natural or swollen. state of eyes, position of tongue; nature of fluid (if any) oozing from mouth, nostrils or ears. → features - natural.  
Eyes - closed, cornea - Hazy  
mouth - closed,  
tongue - inside mouth.  
No oozing from mouth, nostrils and ears.
14. **Condition of skin**—Marks of blood etc. In suspected drowning the presence or absence of cutis anserina to be noted. → Dry & pale.  
Dried blood stains present on both lower limbs.



6. If not examined at Dispensary or Hospital—

- (a) Name of place where examined.
- (b) Distance from Dispensary or Hospital—
- (c) Reason why the body was not sent to the Dispensary or Hospital.

} Not applicable.

II. External Examination—

7. Sex, apparent age, race or caste. male, 42 years.

Description of clothes and of ornaments on the body.

8. Condition of the clothes— Whether wet with water, stained with blood or soiled with vomit or foecal matter.

9. Special marks on the skin such as scars, tattooing etc., any malformations peculiarities, or other marks of identification. State of the teeth.

} One grey colour pant, one faint green colour shirt. Clothes stained with blood, red waist thread one urinary catheter present in situ, cotton bandages present around scrotum and inguinal region soaked in blood.

Handed over to PC on duty.

Body identified by PC on duty. Teeth - intact

In newly born infants, the length and (if possible), the weight of the body to be recorded together with the state of the hair, nails and umbilical cord, its length, whether placenta is attached or not, if present, its size and condition.

} Not applicable.

Internal Examination—

19. Head—

(i) Injuries under the scalp, Intact, no injury.  
their nature.

(ii) Skull—Vault and base Intact, no fracture.  
describe fractures, their sites, dimensions, directions, etc.

(iii) Brain—The appearance of its coverings, size, weight and general condition of the organ itself and any abnormality found in its examination to be carefully noted (weight M. 3 grams F. 2.75 grams).  
meninges - intact  
Brain - intact, pale congested and oedematous.

20. Thorax—

(a) Walls, ribs, cartilages Intact, no fracture.

(b) Pleura Intact, pale.

(c) Larynx, Trachea and Bronchi Intact, no foreign body.

(d) Right Lung } Both lungs intact, pale and oedematous.  
(e) Left Lung }

(f) Pericardium Intact.

(g) Heart with weight } Intact, scanty blood present.

(h) Large vessels }

(j) Additional remarks. Nil.



15. Injuries to external genitalia.  
Indication of purging.

16. **Position of limbs**—Especially of arms and of fingers in suspected drowning the presence or absence of sand or earth within the nails or on the skin of hands and feet.

17. **Surface wounds and injuries**—Their nature, position, dimensions (measured) and directions to be accurately stated—their probable age and causes to be noted.

If bruises be present what is the condition of the subcutaneous tissues?

(N.B.—When injuries are numerous and cannot be mentioned within the space available they should be mentioned on a separate paper which should be signed).

18. Other injuries discovered by external examination or palpation as fractures etc.

Refer to injury No. (6),  
from Column no (17)

(a) Can you say definitely that the injuries shown against serial Nos. 17 and 18 are ante mortem injuries?

Refer to column no (17).

No purging.

→ Straight

1) Sutured wound present on the left eyebrow of length 2cm, with two sutures in situ, on opening size of wound 2cm x 0.5cm x tissue deep, margins irregular, abraded.

2) Contused abrasion present on left malar region of size 2cm x 1cm, red.

3) Lacerated wound present on the right index finger, dorsal aspect, vertically placed of size 2cm x 0.5cm x tissue deep, margins irregular, abraded.

4) Graze abrasion present on the left leg and left knee joint, anterior-lateral aspect of size 22cm x 7cm, directed upward, red.

5) Contused abrasion present on the left ankle joint, lateral aspect of size 10cm x 3cm, red.

6) Lacerated wound present on right side of groin, perineal and left side of thigh, obliquely placed of size 16cm x 5cm x bone deep, underlying pubic bone fractured, left pubic ramus fractured into pieces, underlying muscles, vessels, nerves, lacerated, blood oozing out, margins irregular, right tibia exposing exterior.

7) Contused abrasion present on the right leg, in middle 1/3rd part of size 4cm x 2cm, red.

8) Contused abrasion present on the left flank region iliac region of size 10cm x 3cm, red.

9) Contused abrasion present on the left gluteal region, anterior-lateral aspect of size 2cm x 1cm, red.

10) Multiple contused abrasions present left foot dorsal aspect, involving toes of sizes 2cm x 0.5cm, 1cm x 0.5cm, 0.5cm x 0.5cm, red.

Spine and Spinal Cord — intact, not opened.

Opinion as to the cause  
probable cause of death.

“Haemorrhagic shock due to  
injury to pelvis.”

स. व. कादम  
(Dr. S. V. Kadam)

Resident  
Dept. of Forensic Medicine  
Dr. S. C. G. V. C. Vishnupur  
Nanded-431606.

Dated 11/10/19-200

(Signature)

\*The Spinal Cord need not be examined unless there are any indications of disease, Strychnia poisoning or injury.

**Note**—The report must be written and signed immediately after the examination. Medical Officers will at once despatch a duplicate copy to the Civil Surgeon of their district for record in his office.

Great care should be taken not to cut the viscera before they have been inspected *in situ*.



21. Abdomen—

Walls Intact

Peritoneum } Intact about 1.5 litre of blood present.  
Cavity }

Buccal Cavity, teeth, tongue and Pharynx. Intact, no foreign body.

Desophagus Intact

Stomach and its contents } Intact, 100ml semidigested food present, no abnormal smell perceived.

Small intestine and its contents.

Large intestine and its contents } Intact, partly loaded with faeces and gases.

Liver (with weight) and gall bladder. Intact, pale.

Pancreas and Suprarenals Intact, pale.

Spleen with weight Intact, pale.

Kidneys with weight Intact, pale.

Bladder Intact.

Organs of generations Refer to column no. (17) injury no. (8) eight testis along with its covering exposing to exterior.

Additional remarks with where possible, medical officer's deduction from the state of the contents of the stomach as to time of death and last meal. Nil

State which viscera (if any) have been retained for chemical examination and also quote the numbers on the bottles containing the same. Viscera not preserved.

Drupm No. 912/17  
Date - 11/10/17

Memorandum of a post-mortem examination held at Dr. S.C. Umc Nanded Dispensary Hospital

Sahebrao Sp Kishanrao  
on the dead body of Kanode  
of Village Krishmanagar, Ardhapur  
City

Taluka Ardhapur, District Nanded, by Dr. S.V. Kadam

I. General Particulars—

1. (a) By whom was the corpse sent? P.H.C. Ghodke B.No. 1695  
P.S. Nanded Gramin.
- (b) Name of place from which sent. } casualty  
Dr. S.C. Umc Nanded.
- (c) Distance of place from which sent.
2. By whom was the corpse brought? } P.C. Nagargeje B.No. 1272  
P.S. Nanded Gramin.
3. By whom identified?
4. The date, hour and minute of its receipt. on 11/10/17 at 4:20 pm
- (a) The date, hour and minute of beginning post-mortem examination. on 11/10/17 at 4:45 pm
- (b) The date, hour and minute of ending post-mortem examination. on 11/10/17 at 5:45 pm

5. Substance of accompanying Report from Police Officer or Magistrate, together with the date of death if known. Supposed cause of death or reason, for examination.

As per police inquest and requisition, deceased had road accident on date - 11/10/17, admitted in Dr. S.C. Umc Nanded where he declared brought dead -  
Date of death - 11/10/17.  
Supposed Cause of death - "Head Injury."

पोलीस स्टेशन अर्धापुर  
आयक क्र. 2157/2017  
दिनांक: 15/11/2017



Post No. 914/17 200

Date- 11/10/17

Place <sup>Dispensary</sup> Dr. S.C. GMC Nanded <sub>Civil Hospital</sub> 200

Forwarded to the Police Sub-Inspector P.S. Nanded Gramin.

for information with reference to his No. of 200

Viscera has been preserved. It may please be stated **Immediately** whether examination by the Chemical Analyser is necessary or it is to be destroyed.

*(Signature)*  
**Dr. S.V. Kadam**  
Civil Surgeon or M. M. S. Officer  
**Resident**  
**Dept. of Forensic Medicine**  
**Dr. S.C.G.M.C. Vishnupuri**  
**Nanded-431606**


Copy forwarded with compliments to the Civil Surgeon, for information.

M. M. S. Officer

Seen and examined by the Civil Surgeon,

200

Remarks of the Civil Surgeon,



(if any)

Civil Surgeon

**Condition of body**—  
Whether well-nourished, thin  
or emaciated, warm or cold.

Average built, cold,

11. **Rigor Mortis**—Well-marked,  
slight or absent; whether  
present in the whole body or  
part only.

well marked, present in the whole  
body.

12. Extent and signs of decom-  
position, presence post-  
mortem lividity of buttocks,  
loins, back and thighs or any  
other part. Whether bullae  
present and the nature of  
their contained fluid.  
Condition of the cuticle.

NO signs of decomposition.  
Postmortem lividity present on  
posterior aspect of body except  
pressure areas, not fixed.

13. **Features**—Whether natural  
or swollen, state of eyes,  
position of tongue: nature of  
fluid (if any) oozing from  
mouth, nostrils or ears.

Features - Natural.  
Eyes - closed, cornea - heavy  
mouth - closed.  
Tongue - inside mouth.  
No oozing from mouth, nostrils  
and ear.

14. **Condition of skin**—Marks  
of blood etc. In suspected  
drowning the presence or  
absence of cutis anserina  
to be noted.

Dry, pale.



III. Internal Examination—

19. Head—

(i) Injuries under the scalp, intact, no injury.

(ii) Skull—Vault and base—describe fractures, their sites, dimensions, directions, etc. Intact, no fracture.

(iii) Brain—The appearance of its coverings, size, weight and general condition of the organ itself and any abnormality found in its examination to be carefully noted (weight M. 3 grams F. 2.75 grams).  
meninges - intact.  
Brain - intact, pale, oedematous.

20. Thorax—

- (a) Walls, ribs, cartilages → Intact, fracture of 3rd and 4th rib on right side, in midaxillary line, and fracture of 2nd to 10th rib on left side in midaxillary line, with extravasation of blood in intercostal muscles. fracture margins irregular infiltrated with blood.
- (b) Pleura → Torn at corresponding to fracture of ribs on both sides, with 300ml of blood present in left pleural cavity.
- (c) Larynx, Trachea and Bronchi → Intact, no foreign body.
- (d) Right Lung → Intact, pale, oedematous.
- (e) Left Lung → pale, oedematous with multiple contusions and laceration present on lateral surface of lung.
- (f) Pericardium → Intact.
- (g) Heart with weight
- (h) Large vessels → Intact, blood and blood clots present.
- (i) Additional remarks. Nil.



15. Injuries to external genitalia.  
Indication of purging.

→ No injury.  
No purging.

16. **Position of limbs**—  
Especially of arms and  
of fingers in suspected  
drowning the presence or  
absence of sand or earth  
within the nails or on the  
skin of hands and feet.

→ straight.

17. **Surface wounds and  
injuries**—Their nature, position,  
dimensions (measured)  
and directions to be  
accurately stated—their  
probable age and causes  
to be noted.

1) Lacerated wound present on  
left maxillary region of size  $2\text{cm} \times$   
 $1\text{cm}$  tissue deep, obliquely placed.  
2) contused abrasion present on  
left maxillary region of size  $4\text{cm} \times 3\text{cm}$   
red.

3) Lacerated wound present on  
the chin, on right side of size  
 $1\text{cm} \times 0.5\text{cm}$  tissue deep.

4) Graze abrasion present on the  
left shoulder of size  $3\text{cm} \times 2\text{cm}$ , red,  
directed upward.

5) multiple contused abrasions present  
on the right hand, dorsal aspect  
of size  $1\text{cm} \times 0.5\text{cm}$ ,  $0.7\text{cm} \times 0.5\text{cm}$ ,  
 $0.5\text{cm} \times 0.5\text{cm}$ , red.

If bruises be present what is  
the condition of the  
subcutaneous tissues?

6) contused abrasion present on  
left side of chest,  $5\text{cm}$  above the  
nipple of size  $1\text{cm} \times 0.7\text{cm}$ , red.

(N.B.—When injuries are  
numerous and cannot be  
mentioned within the space  
available they should be  
mentioned on a separate  
paper which should be  
signed).

7) Abrasion present on the left  
side of chest wall in axillary  
region,  $15\text{cm}$  below axilla of size  
 $1\text{cm} \times 1\text{cm}$ , red.

18. Other injuries discovered by  
external examination or  
palpation as fractures etc.

↓  
no fracture.

8) Lacerated wound present on  
the right heel posteromedial  
aspect of size  $10\text{cm} \times 4\text{cm}$  through  
and through, with exposing underlying  
bones to exterior; margins irregular

9) contused abrasion present on  
right elbow, lateral aspect of size  
 $1\text{cm} \times 1\text{cm}$ , red.

(a) Can you say definitely  
that the injuries shown  
against serial Nos. 17  
and 18 are ante mortem  
injuries?

→ Yes, Antemortem injuries.



7  
Spine and Spinal Cord — Intact, not opened.

Opinion as to the cause of probable cause of death. "Blunt trauma to chest and abdomen."

S.V.K.  
(Dr. S.V. Kadam)

Resident  
Dept. of Forensic Medicine  
Dr. S.C.G. V.C. Vishnur  
Nanded-431606

Dated 11/10/17 200

\*The Spinal Cord need not be examined unless there are any  
**Note**—The report must be written and signed immediately after  
despatch a duplicate copy to the Civil Surgeon of their district  
Great care should be taken not to cut the viscera before they have been

21. Abdomen—

Walls Intact .

Peritoneum } One litre of blood present.

Cavity }

Buccal Cavity, teeth, tongue and Pharynx. Intact , no foreign body .

Esophagus Intact .

Stomach and its contents } Intact, 100ml semidigested food present, no abnormal smell perceived.

Small intestine and its contents. }

Large intestine and its contents. } Intact, partly loaded with faeces and gases .

Liver (with weight) and gall bladder. <sup>specimens</sup> Intact. Lower part of right lobe of liver fractured into pieces, parenchyma deep, surrounded by blood clot, pale .

Pancreas and Suprarenals Intact, pale .

Spleen with weight Intact, pale .

Kidneys with weight Intact, pale .

Bladder Intact, empty

Organs of generations Intact .

Additional remarks with → Nil  
where possible, medical officer's deduction from the state of the contents of the stomach as to time of death and last meal.

State which viscera (if any) have been retained for chemical examination and also quote the numbers on the bottles containing the same. Viscera not preserved.



M.P.M. No. 912/17

200

Date - 11/10/17

Place Dispensary  
Civil Hospital

Dr. S.C. Crane Nanded 200

Forwarded to the Police Sub-Inspector P.S. Nanded Grooming.

for information with reference to his No. \_\_\_\_\_ of \_\_\_\_\_ 200

Viscera has been preserved. It may please be stated *immediately* whether examination by the Chemical Analyser is necessary or it is to be destroyed.

*S.V. Kadam*  
(Dr. S.V. Kadam)  
Civil Surgeon or M.M.S. Officer

**Resident**  
Dept. of Forensic Medicine  
Dr. S.C.G.V.C. Vishnupuri  
Nanded-431606

Copy forwarded with compliments to the Civil Surgeon.

for information.

M. M. S. Officer


Seen and examined by the Civil Surgeon,

200

on

Remarks of the Civil Surgeon,

(if any)



Civil Surgeon